Occupational Lung Disease

Arlene Sirajuddin, MD and Jeffrey P. Kanne, MD†*

Abstract: Despite federally mandated safety standards, occupational lung disease remains one of the most common work-related injuries. Inhaled dust can result in a range of tissue injury in the lung and can lead to significant respiratory insufficiency causing death. Although silicosis and coal worker's pneumoconiosis are becoming less common, hypersensitivity pneumonitis is increasingly recognized as an occupational lung disease with new antigens being introduced annually. Imaging, particularly high-resolution computed tomography, is central to the management of occupational lung disease and is useful in diagnosis, assessment of disease activity, and evaluating response to therapy.

Key Words: occupational lung disease, diffuse lung disease, computed tomography

(*J Thorac Imaging* 2009;24:310–320)

Even with safety standards issued by the Occupational Safety and Health Administration and other organizations, such as the National Institute of Occupational Safety and Health, occupational lung disease continues to be one of the most common work-related injuries. New exposures to asbestos arise during industrial maintenance and repair work and during renovation and demolition of buildings containing asbestos insulation. Exposure to silica dust still affects shipyard workers, sandblasters, and coal miners.[1] According to the Centers for Disease Control and Prevention, multiple cases of rapidly progressing pneumoconiosis were reported between the years of 2005 and 2006 among underground coal miners, who began working after the implementation of disease prevention protocols mandated by federal legislation.[2] Hypersensitivity pneumonitis (HP) is an increasingly recognized form of occupational lung disease with new antigens being reported each year.

Further adding to the epidemiology of occupational lung disease is the sometimes long latency between exposure and development of clinical disease with many patients presenting with new respiratory signs and symptoms and radiographic abnormalities years to decades after exposure has ceased.

In this review, we will discuss some of the more common occupational lung diseases and illustrate their respective high-resolution computed tomography (HRCT) findings.

From the *Department of Radiology, University of Maryland School of Medicine, Baltimore, MD; and †Department of Radiology, University of Wisconsin School of Medicine and Public Health, Madison, WI.

Reprints: Jeffrey P. Kanne, MD, Department of Radiology, University of Wisconsin School of Medicine and Public Health, MC 3252, 600 Highland Ave, Madison, WI 53792-3252 (e-mail: jkanne@uwhealth.org).

Copyright © 2009 by Lippincott Williams & Wilkins

SILICOSIS

Silicosis is caused from the inhalation of crystalline silicon dioxide, or silica, and is characterized by lung fibrosis. Although the incidence of silicosis has diminished since the Second World War, it continues to be a major cause of occupational lung disease in exposed workers. Silicosis has a latency of approximately 10 to 30 years, although disease can develop earlier in workers exposed to high quantities of fine silica dust over a relatively short period of time, usually months, a process known as accelerated silicosis.[1,3–6]

Crystalline silica occurs naturally in rock (especially quartz) and sand and also in products such as concrete, ceramics, bricks, and tiles.[1] The occupations that are most commonly associated with silicosis include mining, quarrying, drilling, foundry working, ceramics manufacturing, and sandblasting.[1,4]

Lung injury occurs when inhaled silica particles measuring 1 to 2 mm reach the alveoli and are ingested by alveolar macrophages. The direct cytotoxic effects of silica result in macrophage death with subsequent release of inflammatory cytokines and other substances, which induce the proliferation of fibroblasts. These fibroblasts form hyalinized nodules composed of concentric layers of collagen and silica surrounded by a fibrous capsule. This process is referred to as simple silicosis. When crystalline silica in the periphery of these nodules induces a further fibrotic response, new silicotic nodules form and ultimately lead to complicated silicosis or progressive massive fibrosis (PMF). The lymph nodes become involved when silica-containing macrophages reach the hila and mediastinum.[7]

On HRCT, simple silicosis manifests as multiple small nodules (usually 2 to 5 mm and reaching up to 10 mm), which predominate in the upper and posterior lung zones and are most concentrated in a centrilobular distribution. In the very early or atypical manifestations of silicosis, these nodules may be ill-defined or branching centrilobular opacities, which correspond pathologically to irregular fibrosis around the respiratory bronchioles.[3,4] Coalescence of subpleural silicotic nodules leads to the formation of pseudoplaques (Fig. 1). Hilar and mediastinal lymphadenopathy is often present, and calcification of these lymph nodes may be diffuse or peripheral ("egg-shell") (Fig. 2).[3–5]

Complicated silicosis, or PMF, results from the expansion and confluence of silicotic nodules into larger symmetric opacities, which typically measure more than 1 cm in diameter and most commonly occur in the apical and posterior segments of the upper lobes[3–5] (Fig. 3). These symmetric opacities usually have irregular margins and are uncommonly calcified. Segmental areas of pleural thickening, invagination, and calcification can develop adjacent to areas of PMF in patients in more advanced disease.[8] Over time, with progressive fibrosis and volume loss, these large opacities seem to migrate toward the hila, accompanied by a decrease in profusion of surrounding, a smaller nodules

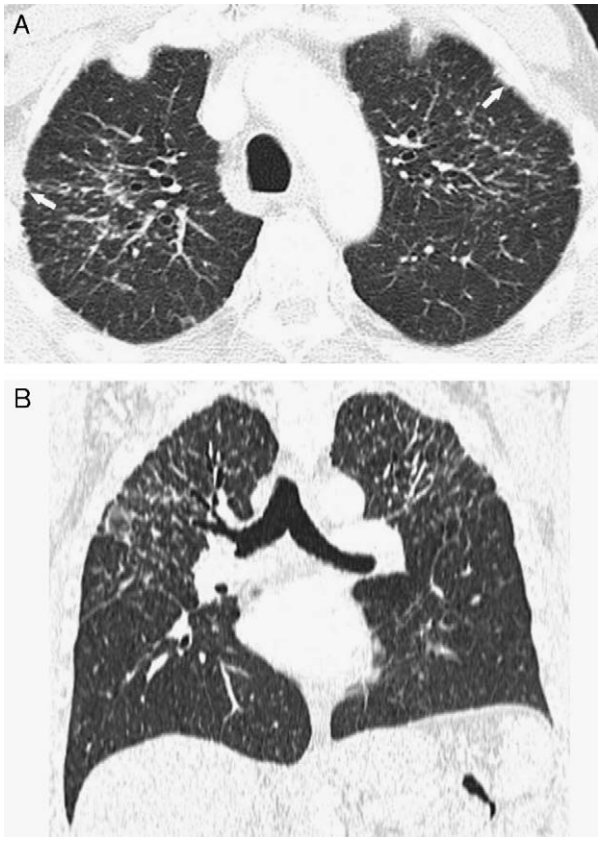

FIGURE 1. A 62-year-old male foundry worker with silicosis. A, HRCT image shows small, well-defined nodules in the upper lobes. Architectural distortion and traction bronchiectasis are mild. Coalescence of subpleural nodules forms pseudoplaques (arrows). B, Coronal reformation shows bilateral upper lobe volume loss and an upper lobe predominance of silicotic nodules.

and development of paracicatricial emphysema between the fibrotic opacities and the pleura. Occasionally, these large opacities become necrotic centrally and can cavitate, the result of either ischemia or tuberculosis.[3,5]

Acute silicosis typically occurs after a very large, acute exposure to silica dust, primarily among sandblasters.[3] Patients usually present with progressive dyspnea within 1 to 3 years after exposure.[6] Reported HRCT findings of acute silicosis include multiple ill-defined centrilobular nodules, patchy ground glass opacity, and lung consolidation.[5,6] In addition, extensive ground glass opacity with superimposed septal thickening ("crazy-paving") may develop, similar to the CT appearance of pulmonary alveolar proteinosis, both of which are characterized by the deposition of periodic acid-Schiff-positive proteinaceous material within the alveoli (Fig. 4).[6] Hilar and mediastinal lymphadenopathy is not uncommon, and the lymph nodes may calcify.[6]

Silicosis predisposes the affected individual to pulmonary tuberculosis, a risk further increased with concomitant smoking.[9] Pulmonary tuberculosis has been reported to occur in up to 25% of patients with silicosis, especially those with accelerated silicosis or PMF.[5] However, the overall incidence of tuberculosis has declined in the industrialized countries. Workers exposed to silica also

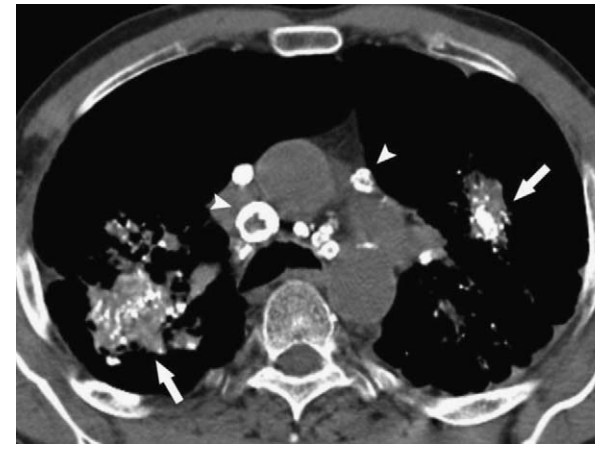

FIGURE 2. A 68-year-old male sandblaster with complicated silicosis progressive massive fibrosis. Unenhanced computed tomography image shows large, partially calcified fibrotic masses in the upper lobes (arrows) and peripherally calcified ("egg-shell") mediastinal and hilar lymph nodes (arrowheads).

have an increased risk of developing chronic interstitial pneumonia and subsequent fibrosis, most commonly usual interstitial pneumonia (UIP).[10] Scleroderma and rheumatoid arthritis have also been linked to silicosis.[11,12] Finally, patients with silicosis have an increased risk of developing lung carcinoma, although it remains unclear if silica itself or subsequent lung fibrosis contributes to this risk.[12]

COAL WORKER'S PNEUMOCONIOSIS

Coal worker's pneumoconiosis (CWP) results from exposure to washed coal or mixed dust consisting of coal, kaolin, mica, and silica.[3,5] Unlike silicosis, the exact mechanism of lung injury and the factors that affect the degree of lung injury are less clear. However, the inhaled quantity of the appropriate-size coal dust particle is likely the most important inciting factor.[13] The role that silica in coal dust plays is in doubt, and several studies have shown that silica has little influence in the development of CWP.[13,14] In contrast, silica likely contributes to the development of PMF in some workers[15] but is not required in others.[16]

FIGURE 3. A 57-year-old male foundry work with complicated silicosis (progressive massive fibrosis). HRCT image shows large fibrotic masses in the upper lobes (arrows) surrounded by numerous smaller nodules.

© 2009 Lippincott Williams & Wilkins

Although the radiographic appearances of silicosis and CWP are similar, the 2 processes differ pathologically. CWP is characterized histologically by aggregates of coal dust and fibroblasts, which comprise the coal macule. The coal macule lacks the hyalinization and laminated collagen typical of the silicotic nodule. Coal macules accumulate around the respiratory bronchioles, resulting in bronchiolectasis. The large opacities of CWP are composed of mineral dust, calcium salts, and proteinaceous material and are distinguished from those of silicosis by the presence of coal dust and the absence of silicotic nodules.

As in silicosis, CWP also has simple and complicated forms, and the HRCT findings of CWP are similar to those of silicosis (Fig. 5). The pneumoconiotic nodules of simple CWP may have less distinct margins than those of silicosis, and they tend to be smaller. Nodule calcification occurs in about 10% to 20% of patients.[5] As in silicosis, the subpleural nodules of CWP can aggregate to form pseudoplaques.[3] Tiny foci of centrilobular emphysema may also be present.[17] Lymph node calcification occurs less frequently in CWP than in silicosis.

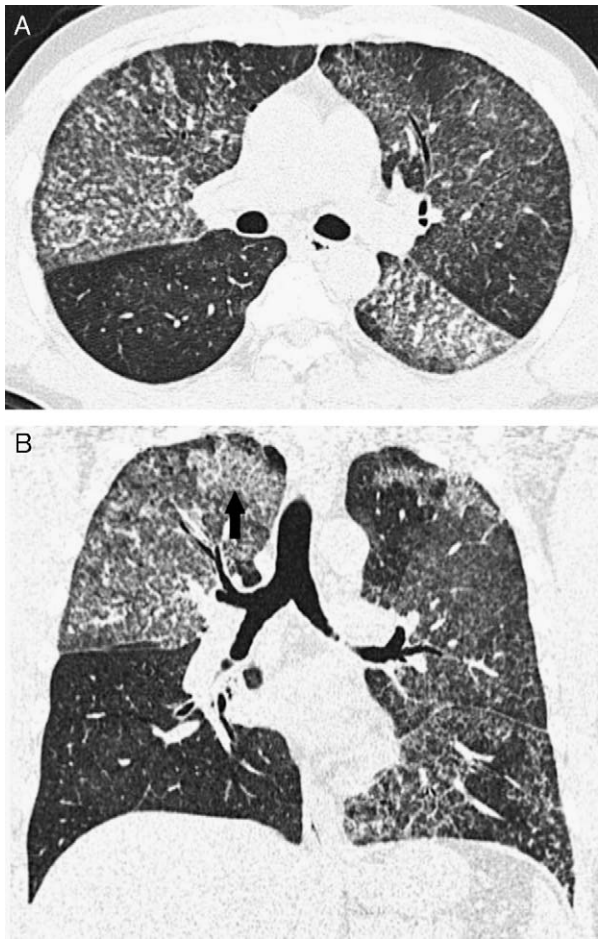

FIGURE 4. A 28-year-old mason's apprentice with silicoproteinosis. A, HRCT image shows a geographic distribution of ground glass opacity, reticulation, and tiny nodules with foci of normal lung. B, Coronal reformation shows extensive but asymmetric involvement of both lungs with ''crazy-paving'' in the right lung apex (arrow).

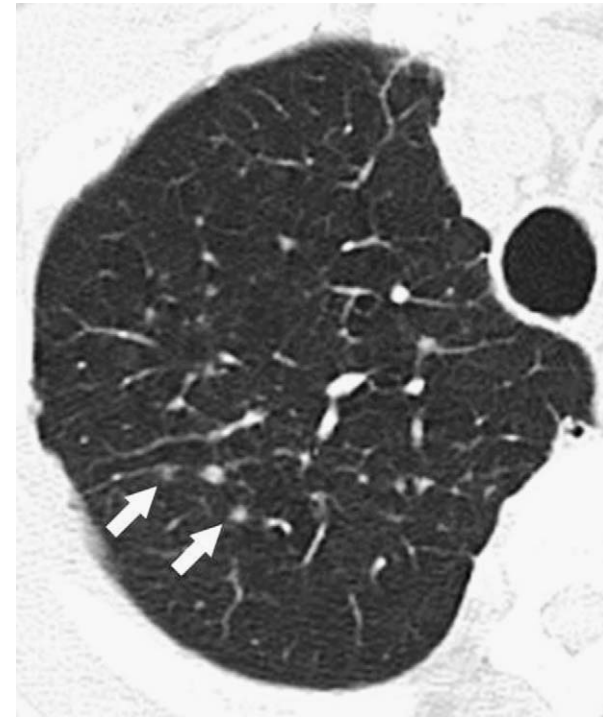

FIGURE 5. A 50-year-old coal miner with simple Coal worker's pneumoconiosis. Unenhanced computed tomography image shows small, poorly defined nodules in the right upper lobe with a posterior predominance (arrows).

PMF can also develop in patients with CWP, although this occurs less frequently than in patients with silicosis, and PMF is unusual in workers with less than 20 years exposure to coal dust.[18] Coal workers with early PMF may be asymptomatic, but with progression, which is usually very slow, dyspnea may ensue as pulmonary function declines. As with silicosis, paracicatricial emphysema can develop concurrent with growth of large opacities. Emphysema is likely the major factor contributing to the decline of lung function in patients with CWP as the degree of respiratory impairment correlates better with the amount of emphysema than with the small nodule and large opacities of PMF.[19] The large opacities can cavitate, with or without infection, and patients may report coughing up black sputum (melanoptysis). The possibility of mycobacterial superinfection should be entertained when cavitation is present.

Interstitial lung fibrosis develops in less than 20% of at-risk coal workers but is associated with an increased incidence of lung carcinoma. On HRCT, the pattern of fibrosis is similar to those of UIP and nonspecific interstitial pneumonia.[20]

ASBESTOS-RELATED DISEASE

Asbestos is a group of heterogeneous, naturally occurring fibrous silicate minerals, known since antiquity for their heat-resistant properties. It has been used across industries and manufacturing and can be found in brake linings and pads, tiles, bricks, insulation material, and linings of furnaces and ovens.

Asbestos is grouped into 2 major categories on the basis of the physical characteristics of the fibers. Serpentine fibers are smooth, curly, and flexible and are made of tiny

 © 2009 Lippincott Williams & Wilkins

thread-like subunits. Chrysotile is the most common serpentine asbestos used, accounting for over 90% of asbestos in the United States. Amphibole fibers are stiff and straight and vary in their other physical properties. Crocidolite, amosite, tremolite, antophyllite comprise the most common amphiboles. Although the relatively high carcinogenic and fibrogenic potentials of amphiboles, particularly crocidolite, have led to a decline in their usage, all asbestos fibers have been linked to carcinoma, mesothelioma, and lung fibrosis.[21]

Asbestos-related conditions in the chest include pleural effusion, pleural plaques, diffuse pleural thickening, rounded atelectasis, asbestosis, mesothelioma, and lung carcinoma,[21,22] and all result from inhalation of asbestos fibers.[5,22] The latency from exposure to development of one of these conditions ranges over decades, accounting for the continued development asbestos-related diseases despite improved occupational safety and decline in asbestos usage.

Although quite uncommon, pleural effusion is the earliest manifestation of asbestos-related pleural disease and usually occurs 10 years after exposure, but may develop as early as 5 years or as late as 20 years.[22] Patients are often asymptomatic, but pleuritic chest pain, fever, and leukocytosis may occur. Benign asbestos-related pleural effusions are usually exudative with or without a small amount of blood and uncommonly exceed 500 mL. They may be either unilateral or bilateral. As the pleural effusion regresses, diffuse thickening of the affected visceral pleura develops in slightly more than half of patients.[23] Owing to the relative high risk of developing lung carcinoma or mesothelioma, benign asbestos-related pleural effusion is a diagnosis of exclusion in those exposed to asbestos. Significant chest pain should raise the specter of mesothelioma or other malignant effusion.

Diffuse pleural thickening from asbestos exposure, in contrast to pleural plaques, is often associated with significant respiratory impairment, and, for example, benign asbestos pleural effusion, is far less specific for asbestos exposure than pleural plaques as empyema, hemothorax, and thoracic surgery can cause diffuse pleural thickening. Typically the visceral pleura is involved, and pleural thickening is

FIGURE 6. A 72-year-old male shipyard worker with asbestos-related pleural disease. Unenhanced computed tomography sagittal reformation shows numerous calcified and noncalcified pleural plaques (arrowheads).

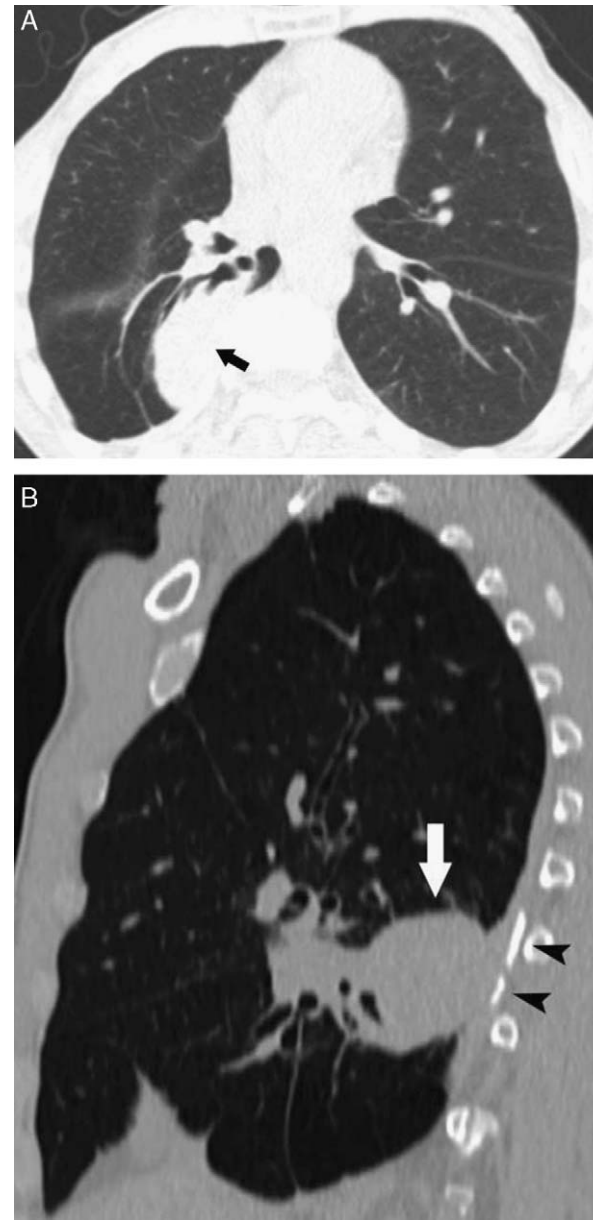

FIGURE 7. A 74-year-old man with asbestos-related pleural disease and rounded atelectasis. A, Unenhanced computed tomography image shows a round, subpleural focus of consolidation (arrow) with right lower lobe volume loss. B, Sagittal reformations shows the focus of rounded atelectasis (arrow) intimately related to the adjacent pleural plaque and thickening (arrowheads).

© 2009 Lippincott Williams & Wilkins

commonly the consequence of earlier asbestos-related pleural effusion. The precise definition of diffuse pleural thickening on both chest radiographs and CT varies. Lynch et al[24] define diffuse pleural thickening as more than 3 mm in thickness and extending more than 5 cm in transverse dimension and more 8 cm in craniocaudad extent.

Pleural plaques (Fig. 6) are the most common manifestation of asbestos-related pleural disease and typically develop 20 to 30 years after exposure.[3] They are formed from hyalinized fibrous tissue on the parietal pleural and frequently undergo dystrophic calcification with growth and over time. Asbestos fibers, particularly chrysotile, have been found in these plaques on electron microscopy studies, indicating transpleural migration and aggregation occur.[25] Pleural plaques may or may not be associated with restrictive physiologic impairment. Impairment, if present, is usually quite mild and may be attributable, at least in part, to microscopic lung fibrosis.[26,27]

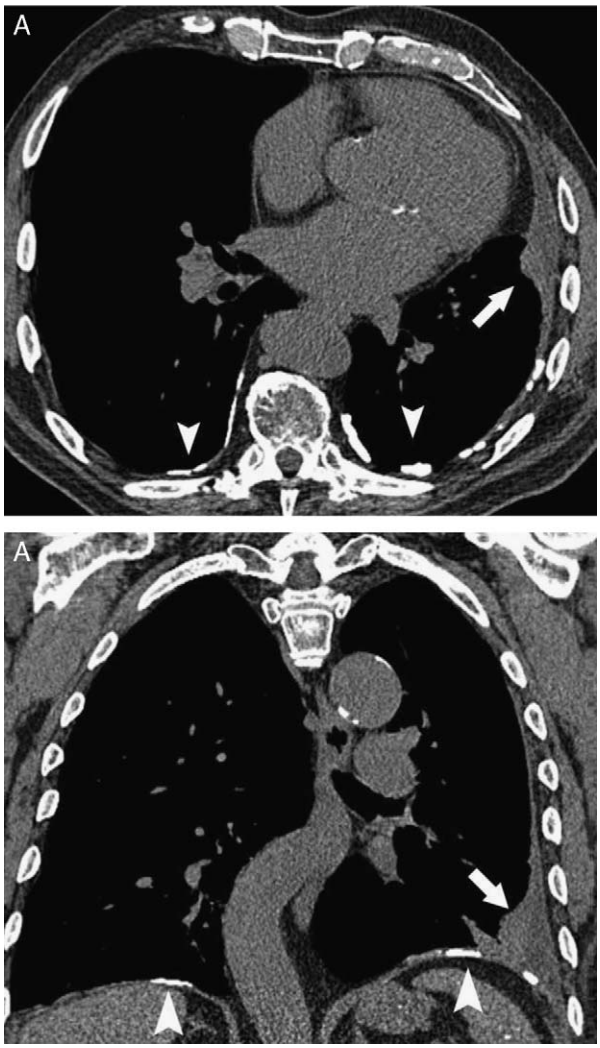

FIGURE 8. A 65-year-old male retired construction worker with asbestos-related pleural disease. A and B, Transverse and coronal-unenhanced computed tomography images show bilateral calcified and noncalcified pleural plaques (arrowheads) and a focus of rounded atelectasis (arrow) adjacent to localized pleural thickening.

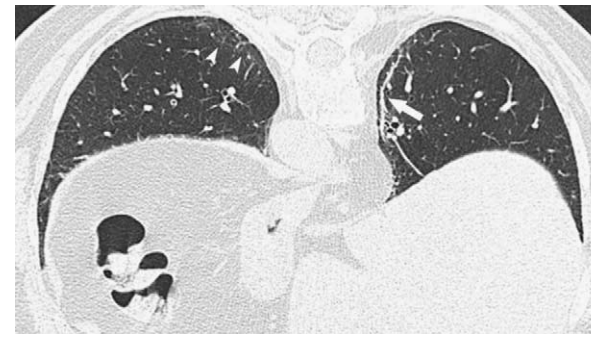

FIGURE 9. A 72-year-old man with mild asbestosis. Prone HRCT image shows subpleural ground glass opacity (arrowheads) and a curvilinear subpleural band (arrow).

HRCT is superior to chest radiograph in detecting pleural plaques and easily distinguishes extrapleural fat from pleural plaques. Pleural plaques most commonly develop along the posterolateral chest wall between the sixth and tenth ribs and along the central diaphragm. Their margins may be smooth or irregular.

Rounded atelectasis related to asbestos is also called asbestos pseudotumor (Figs. 7, 8). It is caused by

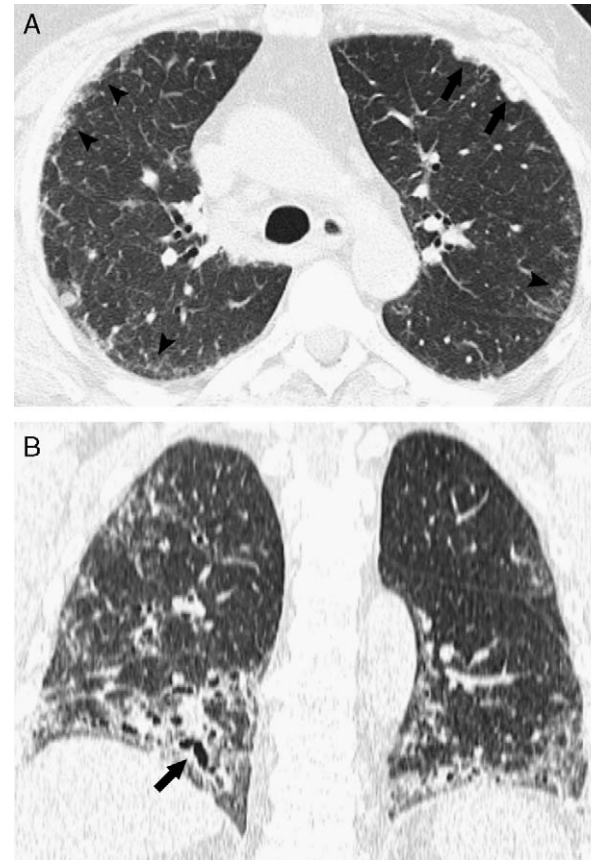

FIGURE 10. A 70-year-old man with asbestosis. A, HRCT image shows subpleural nodules and ground glass opacity (arrowheads) and calcified pleural plaques (arrows). B, Coronal reformation shows more extensive fibrosis in the lung bases with traction bronchiectasis (arrow).

© 2009 Lippincott Williams & Wilkins

invagination of thickened visceral pleura into the lung, resulting in atelectasis of the underlying lung. Rounded atelectasis is not specific to asbestos-related pleural disease and can develop in any condition that leads to a pleural exudate or pleural fibrosis. Although most causes of rounded atelectasis are benign, it may develop with mesothelioma.[28] On HRCT, rounded atelectasis manifests as a peripheral mass abutting the pleura with or without lung distortion and with a curving tail of bronchovascular structures spiraling into the mass ("comet tail sign").[3,22] The adjacent pleura is thickened, and signs of lobar volume loss are usually present.

Asbestosis that is defined as interstitial fibrosis as a result of asbestos exposure has a latency of approximately 20 years.[3] Asbestosis preferentially involves the lower and subpleural regions of the lungs. HRCT findings include subpleural curvilinear opacities (Fig. 9), ground glass opacity, subpleural poorly defined centrilobular nodules, thickening of the interlobular septa, parenchymal bands, traction bronchiectasis (Fig. 10), and occasionally honeycombing.[3,22] A mosaic pattern of attenuation can also be present in asbestosis.[29] Ground glass opacity is an uncommon finding, which may be present in the subpleural area.[3] In patients with suspected asbestosis, prone imaging may be helpful to differentiate early fibrosis from atelectasis.[3,5] The presence of pleural disease and poorly defined centrilobular nodules in the subpleural regions is helpful in differentiating asbestosis from other causes of pulmonary fibrosis.[5,29] As a rule, the more subtle findings of lung fibrosis should be present bilaterally in nondependent lung at multiple levels.[30]

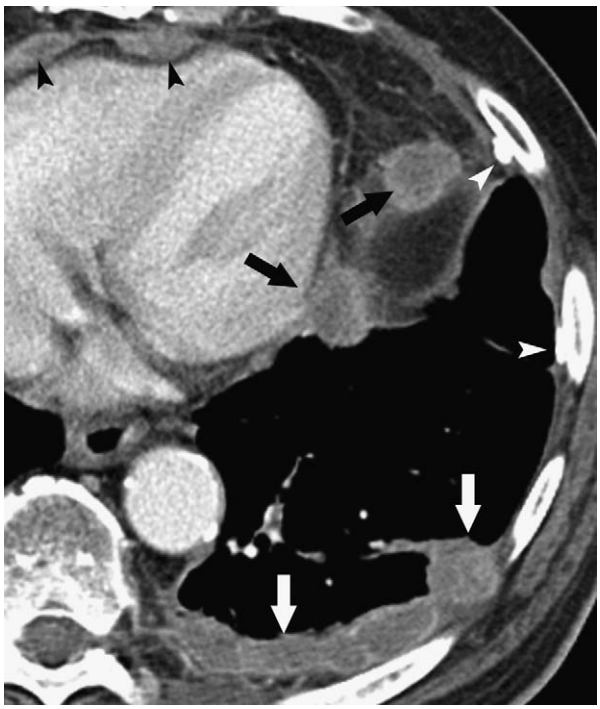

FIGURE 11. A 69-year-old man with metastatic mesothelioma. Contrast-enhanced computed tomography image shows multiple pleural nodules (white arrows) and a small pleural effusion. Pericardial (black arrowheads) and mediastinal (black arrows) metastases are present, and there are small calcified asbestos-related pleural plaques (white arrowheads).

Mesothelioma (Fig. 11) and bronchogenic carcinomas can arise in the setting of asbestos exposure.[5] Mesothelioma can develop within either pleural layer, and an associated pleural effusion is often present.[22] Mesothelioma may result in smooth or nodular pleural thickening and encasement of the lung. Mesotheliomas can invade the chest wall, diaphragm, and mediastinum.[22] Bronchogenic carcinoma is also strongly linked to asbestos exposure with smoking and asbestos having a synergistic effect.[21,22] Extrathoracic neoplasms associated with asbestos exposure include peritoneal mesotheolioma, leukemia, gastrointestinal carcinoma, and head and neck carcinomas.[31]

HYPERSENSITIVITY PNEUMONITIS

HP, also known as extrinsic allergic alveolitis, is a diffuse granulomatous interstitial lung disease involving the lungs and terminal airways. It develops as a result of the repeated inhalation of antigenic organic and low molecular weight inorganic particles.[3,32–35] HP was first described in farmers and bird breeders, resulting in terms such as "farmer's lung" and "bird fancier's lung," respectively. However, numerous microbial and animal antigens and some inorganic compound have been associated with HP.

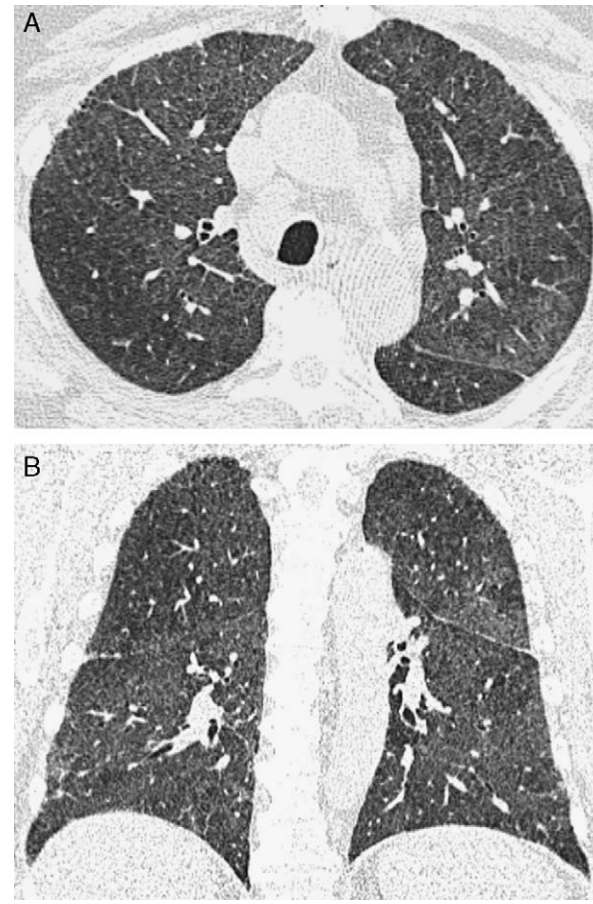

FIGURE 12. A 52-year-old male farmer with subacute hypersensitivity pneumonitis. A and B, Transverse and coronal HRCT images show innumerable poorly defined centrilobular nodules patchy foci of lobular hyperlucency, suggestive of air trapping.

© 2009 Lippincott Williams & Wilkins

Common industrial antigens causing HP include isocynates (paint sprays), plastics (packing plants), *Mycobacterium avium* complex (metal working fluids), *Aspergillus* (agriculture), and thermophilic actinomyces (agriculture). Complicating the diagnosis of HP is the fact that identifying the causative antigen can be quite difficult and may not be found in up to one-third of histologically proven HP.[36]

Histologically, cellular bronchiolitis, poorly formed nonnecrotizing granulomata, and lymphoplasmocytic interstitial pneumonitis comprise HP, although not all features are present in every patient. Giants cells and foci of organizing pneumonia may also be present.[37] Fibrosis similar to UIP or nonspecific interstitial pneumonia can occur in the chronic form.

HP is traditionally grouped both clinically and radiographically into acute, subacute, and chronic forms.[3,32,35] However, significant overlap of findings occurs, and only the presence of lung fibrosis can indicate chronic disease.

The acute form is very uncommon and is mediated by immune complex tissue injury, manifesting with signs and symptoms such as fever, cough, and dyspnea occurring within 4 to 6 hours of a heavy antigen exposure in individuals who have been earlier sensitized. HRCT findings in the acute phase consist of diffuse ground glass opacity, reticular opacities, and small poorly defined nodules predominating in the lower lung zones.[38]

Subacute HP (Figs. 12, 13) occurs with chronic low-level exposure to the offending antigen. HRCT findings of subacute HP include patchy or diffuse ground glass opacity, small (< 5 mm) and poorly defined centrilobular nodules, and patchy lobular air trapping. Sparse thin-walled cysts occur in about 10% of patients with subacute HP, and mild mediastinal lymphadenopathy develops in about half of patients. With early diagnosis and elimination of the antigen exposure, the prognosis of subacute HP is very favorable.[32]

The HRCT findings of chronologically chronic HP (Figs. 14, 15) are extremely variable. They may include poorly defined centrilobular nodules and lobular air trapping similar to "subacute" HP. In addition, peripheral and peribronchial fibrosis may be present manifesting as reticulation, traction bronchiectasis, volume loss, and, in more advanced disease, honeycombing. Upper, mid, and lower lung zone predominances have all been described. Some patients may develop obstructive lung disease, and emphysema has been described.[32,33,35,39]

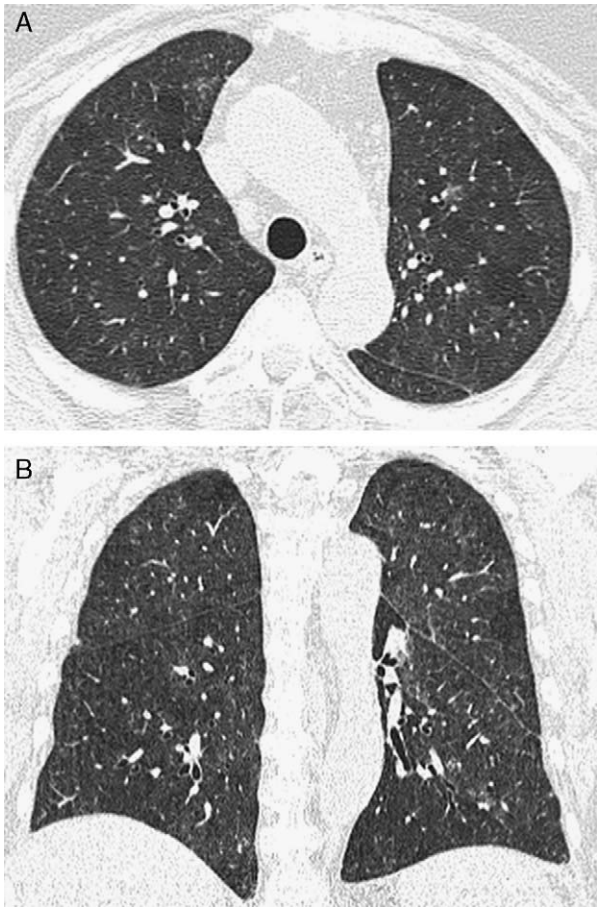

FIGURE 13. A 48-year-old female artist who developed subacute hypersensitivity pneumonitis after using wild turkey feathers to make collages. A and B, Transverse and coronal HRCT images show patchy ground glass opacity and lobular hyperlucency, suggestive of air trapping.

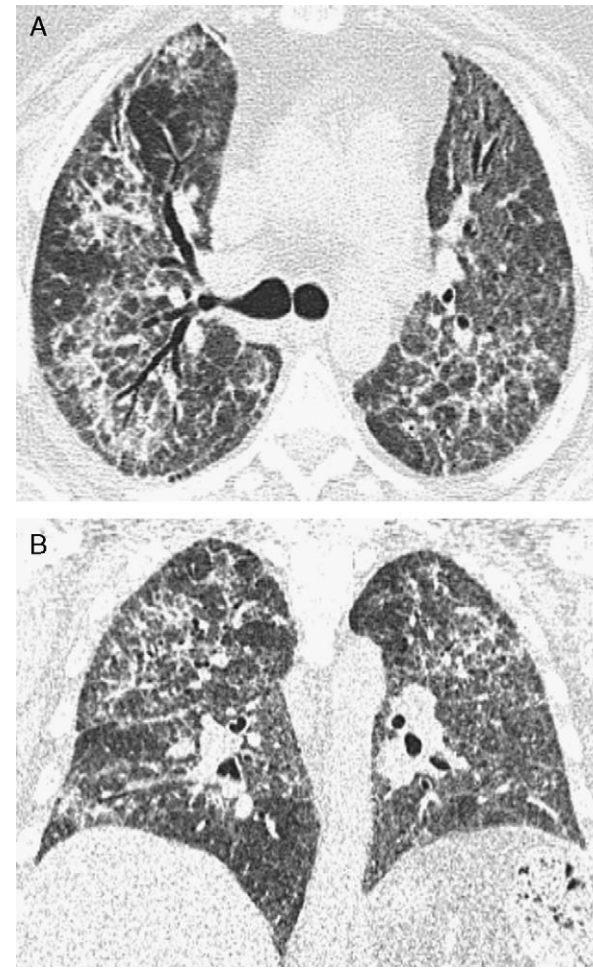

FIGURE 14. A 34-year-old female bakery employee with chronic hypersensitivity pneumonitis from wheat flour. A and B, Transverse and coronal HRCT images show extensive ground glass opacity, reticulation, traction bronchiectasis, and lobular hyperlucency, suggestive of air trapping.

© 2009 Lippincott Williams & Wilkins

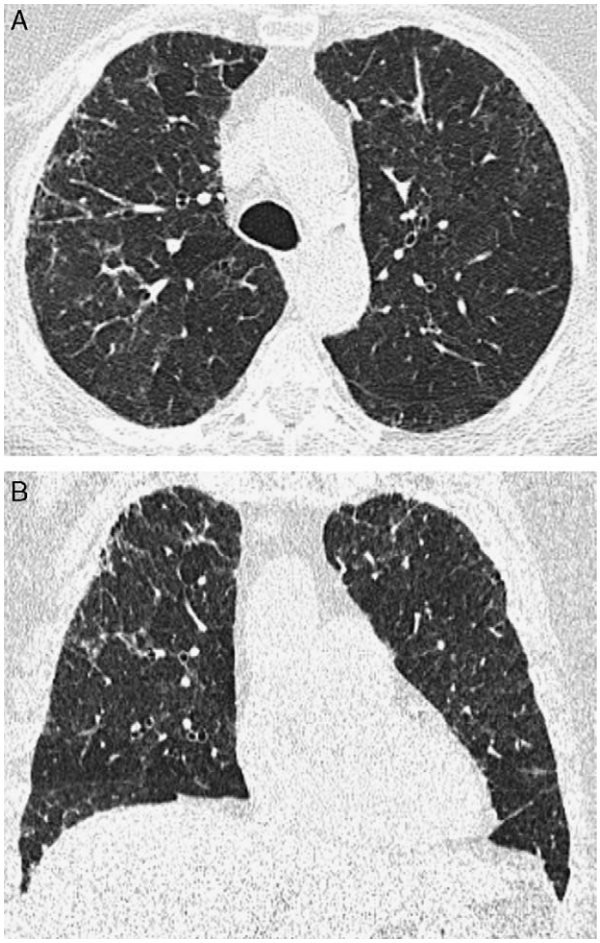

FIGURE 15. A 45-year-old male auto body shop employee with chronic hypersensitivity pneumonitis from chronic isocyanate exposure. A and B, Transverse and coronal HRCT images show patchy ground glass opacity and subpleural and peribronchial reticulation.

Chronic HP may progress, leading to end-stage lung disease with respiratory insufficiency, and ultimately death factors that predict mortality in chronic HP include fibrosis on HRCT, marked pulmonary function test abnormalities, and the presence of crackles on lung examination.[32] The 5-year mortality in chronic HP is as high as 30%, and in the subset of the fibrotic type of chronic HP, the 5-year mortality reaches 61%.[33]

BERYLLIOSIS

Berylliosis, although technically a pneumoconiosis, differs from the other pneumoconioses in that it is a chronic granulomatous hypersensitivity reaction to inhaled beryllium dust, fumes, and salts, and the amount and length of exposure do not correlate with the incidence and severity of disease.[3,5,40,41] Increase in beryllium use across industries such as nuclear power, aerospace, ceramics and metal manufacturing, and dentistry has resulted in a concurrent increase in chronic berylliosis.[41]

Berylliosis primarily affects the lungs and occurs in 1% to 15% of those exposed.[42,43] Berylliosis has both acute and chronic forms, although current workplace protections have virtually eliminated acute disease. Berylliosis may

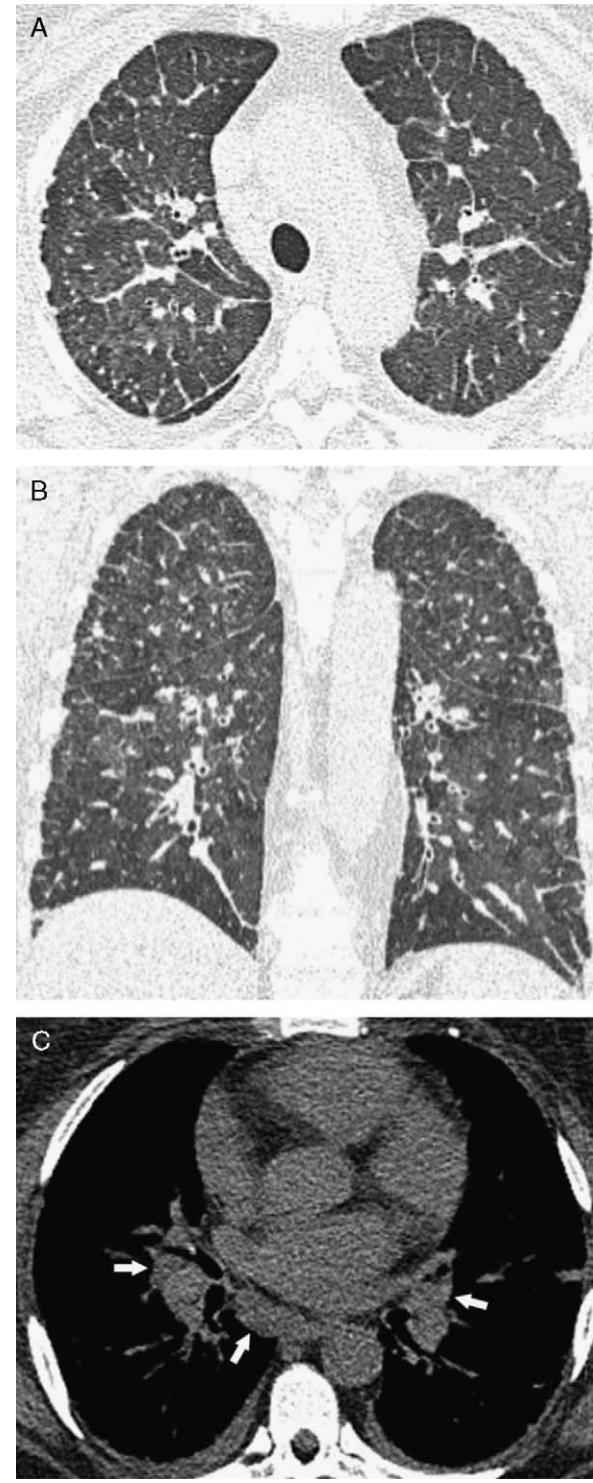

FIGURE 16. A 48-year-old female nuclear power plant worker with chronic berylliosis. A and B, Transverse and coronal HRCT images show interlobular septal thickening, small perilymphatic nodules (subpleural, peribronchial), and a mosaic pattern of attenuation. C, Transverse HRCT image (mediastinal window settings) shows bilateral hilar and mediastinal lymphadenopathy (arrows) and small pleural effusions.

© 2009 Lippincott Williams & Wilkins

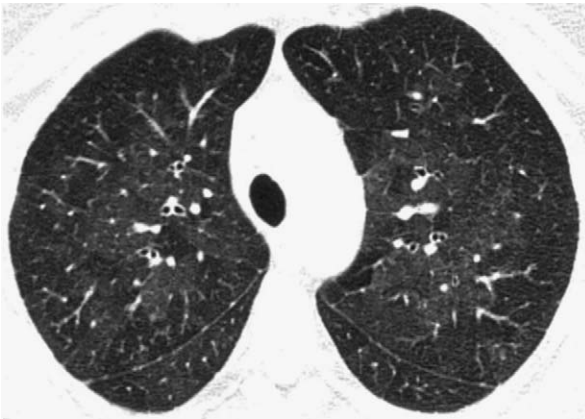

FIGURE 17. A 53-year-old female factory worker with chronic berylliosis. HRCT image demonstrates bilateral patchy ground glass opacity.

develop in those with minimal exposure whereas those with chronic exposure can remain disease free. Signs and symptoms, which include dyspnea on exertion, cough, chest pain, and fatigue, may develop as early as a few months after exposure to as late as 40 years.

The histopathologic findings of chronic berylliosis are identical to those of sarcoidosis and include formation noncaseating granulomata and a mononuclear cellular infiltrate. Interstitial fibrosis is variably present. The diagnosis is made by documenting beryllium exposure, showing a beryllium-specific hypersensitivity response (with the beryllium lymphocyte proliferation test),[43] and showing granulomata, a mononuclear cellular infiltrate, or both in the absence of infection.

HRCT findings of chronic berylliosis (Figs. 16, 17) are similar to those of sarcoidosis[44] and include small nodules distributed along the bronchovascular bundles, smooth or nodular interlobular septal thickening, ground glass opacity, and bronchial wall thickening. Mediastinal and hilar lymphadenopathy occurs less frequently than in sarcoidosis, present in only about 25% of patients.[43] Honeycombing and conglomerate masses are rare and present in advanced disease.

HARD METAL PNEUMOCONIOSIS

Hard metal pneumoconiosis, formerly classified as giant cell interstitial pneumonia, results from exposure to tungsten carbide, cobalt, and diamond dust produced in hard-metal industry.[3,6] Cobalt is believed to be the primary contributor of lung disease. Hard metal pneumoconiosis is a spectrum of diseases including occupational asthma and obliterative bronchiolitis, the earliest manifestations

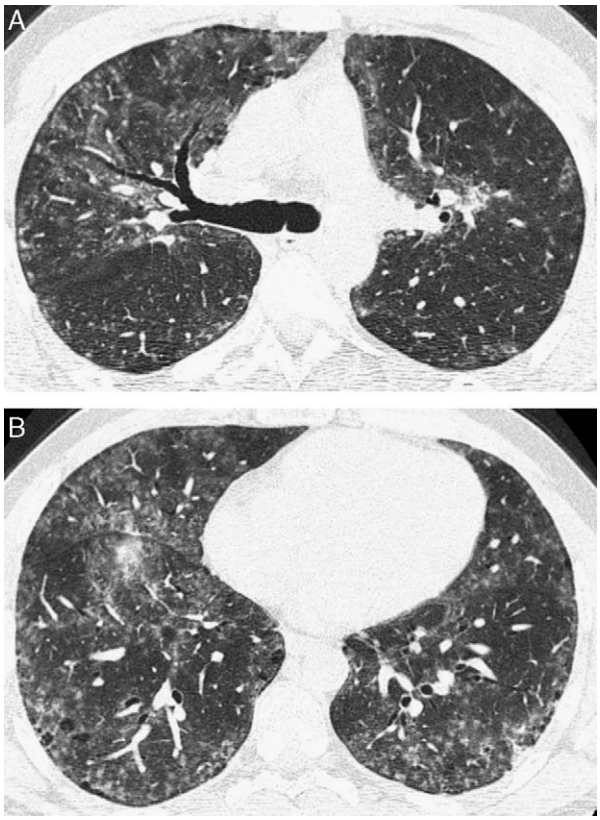

FIGURE 18. A 34-year-old male machinist with hard metal pneumoconiosis from 15-year exposure to tungsten carbide dust. A and B, HRCT images show patchy ground glass opacity and multiple poorly defined nodules. Courtesy of Nestor L. Müller, MD, PhD (Vancouver, British Columbia).

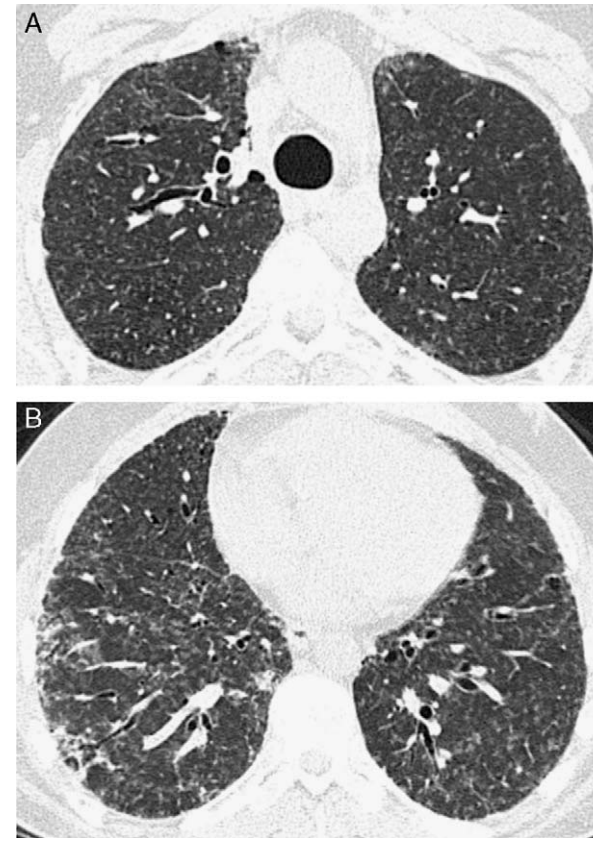

FIGURE 19. A 28-year-old male grinder with hard metal pneumoconiosis from exposure to tungsten carbide and cobalt dust. A, HRCT image shows numerous poorly defined centrilobular nodules in the upper lobes. B, HRCT image more caudad shows numerous poorly defined centrilobular nodules and more well-defined nodules.

© 2009 Lippincott Williams & Wilkins

of disease, and giant cell interstitial pneumonia and interstitial fibrosis.[5,45]

HRCT findings of hard metal pneumoconiosis consist primarily of bilateral ground glass opacities, tiny nodules, reticular opacities, traction bronchiectasis, and consolidation (Figs. 18, 19). A lower lobe predominance has been described. Honeycombing is a late, uncommon finding.[45–47]

FLAVOR WORKER'S LUNG

Flavor worker's lung is a newly recognized occupational lung disease characterized by the development of obliterative bronchiolitis after exposure to diacetyl (2,3-butanedione), a ketone used in the butter flavoring of microwave popcorn. Flavor worker's lung was first described in 2000 in 8 workers who developed progressive dyspnea and obstructive lung disease in a Missouri popcorn flavoring plant.[48] National Institute of Occupational Safety and Health scientists investigated the plant and found numerous volatile compounds, of which diacetyl was the most predominant, in the mixing and packing rooms of the popcorn flavoring plant.

HRCT findings of flavor worker's lung are similar to other forms of obliterative bronchiolitis and include mosaic attenuation with air trapping on expiratory imaging (Fig. 20).[49] Bronchial wall thickening and bronchiectasis may also be present.

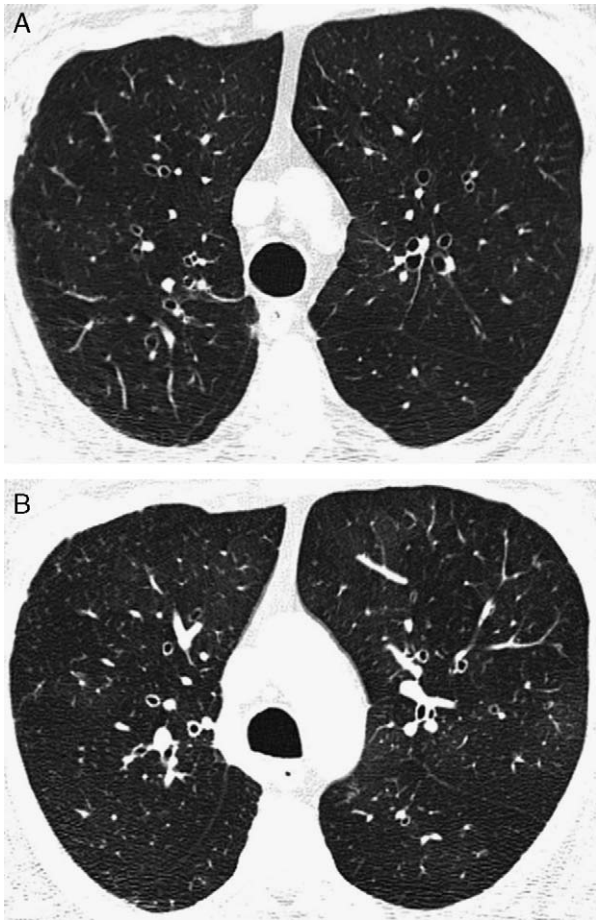

FIGURE 20. Popcorn plant worker with obliterative bronchiolitis from diacetyl exposure. A, Inspiratory HRCT image shows a mosaic pattern of attenuation. B, Expiratory HRCT image shows persistent hypolucent foci, compatible with air trapping. Courtesy of David A. Lynch, MB (Denver CO).

CONCLUSIONS

Occupational lung disease continues to affect workers across industries even with increased occupational and environmental safeguards. HRCT findings in conjunction with a thorough occupational and environmental history and physical examination are essential for diagnosing the occupational lung disease.

REFERENCES

1. Bang KM, Attfield MD, Wood JM, et al. National trends in silicosis mortality in the United States, 1981 to 2004. *Am J Ind Med*. 2008;51:633–639.
2. Centers for Disease Control and Prevention (CDC). Advanced pneumoconiosis among working underground coal miners—Eastern Kentucky and Southwestern Virginia, 2006. *MMWR Morb Mortal Wkly Rep*. 2007;56:652–655.
3. Akira M. High-resolution CT in the evaluation of occupational and environmental disease. *Radiol Clin North Am*. 2002;40:43–59.
4. Antao VC, Pinheiro GA, Terra-Filho M, et al. High-resolution CT in silicosis: correlation with radiographic findings and functional impairment. *J Comput Assist Tomogr*. 2005;29:350–356.
5. Chong S, Lee KS, Chung MJ, et al. Pneumoconiosis: comparison of imaging and pathologic findings. *Radiographics*. 2006;26:59–77.
6. Marchiori E, Souza CA, Barbassa TG, et al. Silicoproteinosis: high-resolution CT findings in 13 patients. *AJR Am J Roentgenol*. 2007;189:1402–1406.
7. Castranova V, Vallyathan V. Silicosis and coal workers' pneumoconiosis. *Environ Health Perspect*. 2000;108(Suppl 4): 675–684.
8. Arakawa H, Honma K, Saito Y, et al. Pleural disease in silicosis: pleural thickening, effusion, and invagination. *Radiology*. 2005;236:685–693.
9. Leung CC, Yew WW, Law WS, et al. Smoking and tuberculosis among silicotic patients. *Eur Respir J*. 2007;29:745–750.
10. Arakawa H, Johkoh T, Honma K, et al. Chronic interstitial pneumonia in silicosis and mix-dust pneumoconiosis: its prevalence and comparison of CT findings with idiopathic pulmonary fibrosis. *Chest*. 2007;131:1870–1876.
11. Steen VD. Occupational scleroderma. *Curr Opin Rheumatol*. 1999;11:490–494.
12. American Thoracic Society. Adverse effects of crystalline silica exposure. American thoracic society committee of the scientific assembly on environmental and occupational health. *Am J Respir Crit Care Med*. 1997;155:761–768.
13. Hurley JF, Burns J, Copland L, et al. Coalworkers' simple pneumoconiosis and exposure to dust at 10 British coalmines. *Br J Ind Med*. 1982;39:120–127.
14. Morgan WK, Lapp NL. Respiratory disease in coal miners. *Am Rev Respir Dis*. 1976;113:531–559.
15. Naeye RL, Dellinger WS. Coal workers' pneumoconiosis. Correlation of roentgenographic and postmortem findings. *JAMA*. 1972;220:223–227.
16. Nagelschmidt G, Rivers D, King EJ, et al. Dust and collagen content of lungs of coal-workers with progressive massive fibrosis. *Br J Ind Med*. 1963;20:181–191.
17. Akira M, Higashihara T, Yokoyama K, et al. Radiographic type p pneumoconiosis: high-resolution CT. *Radiology*. 1989; 171:117–123.
18. Williams JL, Moller GA. Solitary mass in the lungs of coal miners. *Am J Roentgenol Radium Ther Nucl Med*. 1973;117: 765–770.
19. Bergin CJ, Muller NL, Vedal S, et al. CT in silicosis: correlation with plain films and pulmonary function tests. *AJR Am J Roentgenol*. 1986;146:477–483.

© 2009 Lippincott Williams & Wilkins

20. Katabami M, Dosaka-Akita H, Honma K, et al. Pneumoconiosis-related lung cancers: preferential occurrence from diffuse interstitial fibrosis-type pneumoconiosis. *Am J Respir Crit Care Med*. 2000;162:295–300.
21. Hosoda Y, Hiraga Y, Sasagawa S. Railways and asbestos in Japan (1928 to 1987)—epidemiology of pleural plaques, malignancies and pneumoconioses. *J Occup Health*. 2008;50:297–307.
22. Roach HD, Davies GJ, Attanoos R, et al. Asbestos: when the dust settles an imaging review of asbestos-related disease. *Radiographics*. 2002;22 spec No:S167–S184.
23. McLoud TC, Woods BO, Carrington CB, et al. Diffuse pleural thickening in an asbestos-exposed population: prevalence and causes. *AJR Am J Roentgenol*. 1985;144:9–18.
24. Lynch DA, Gamsu G, Aberle DR. Conventional and high resolution computed tomography in the diagnosis of asbestos-related diseases. *Radiographics*. 1989;9:523–551.
25. Kannerstein M. Recent advances and perspectives relevant to the pathology of asbestos-related diseases in man. *IARC Sci Publ*. 1980;149–162.
26. Schwartz DA, Galvin JR, Dayton CS, et al. Determinants of restrictive lung function in asbestos-induced pleural fibrosis. *J Appl Physiol*. 1990;68:1932–1937.
27. Shih JF, Wilson JS, Broderick A, et al. Asbestos-induced pleural fibrosis and impaired exercise physiology. *Chest*. 1994; 105:1370–1376.
28. Munden RF, Libshitz HI. Rounded atelectasis and mesothelioma. *AJR Am J Roentgenol*. 1998;170:1519–1522.
29. Akira M, Yamamoto S, Inoue Y, et al. High-resolution CT of asbestosis and idiopathic pulmonary fibrosis. *AJR Am J Roentgenol*. 2003;181:163–169.
30. Gamsu G, Salmon CJ, Warnock ML, et al. CT quantification of interstitial fibrosis in patients with asbestosis: a comparison of two methods. *AJR Am J Roentgenol*. 1995;164:63–68.
31. Fraser RS, Muller NL, Colman NC, et al. *Fraser and Pare's Diagnosis of Diseases of the Chest*. 4th ed. Philadelphia: Saunders; 1999.
32. Hanak V, Golbin JM, Hartman TE, et al. High-resolution CT findings of parenchymal fibrosis correlate with prognosis in hypersensitivity pneumonitis. *Chest*. 2008;134:133–138.
33. Sahin H, Brown KK, Curran-Everett D, et al. Chronic hypersensitivity pneumonitis: CT features comparison with pathologic evidence of fibrosis and survival. *Radiology*. 2007;244: 591–598.
34. Schreiber J, Knolle J, Sennekamp J, et al. Sub-acute occupational hypersensitivity pneumonitis due to low-level exposure to diisocyanates in a secretary. *Eur Respir J*. 2008;32:807–811.
35. Silva CI, Churg A, Muller NL. Hypersensitivity pneumonitis: spectrum of high-resolution CT and pathologic findings. *AJR Am J Roentgenol*. 2007;188:334–344.
36. Vourlekis JS, Schwarz MI, Cherniack RM, et al. The effect of pulmonary fibrosis on survival in patients with hypersensitivity pneumonitis. *Am J Med*. 2004;116:662–668.
37. Coleman A, Colby TV. Histologic diagnosis of extrinsic allergic alveolitis. *Am J Surg Pathol*. 1988;12:514–518.
38. Silver SF, Muller NL, Miller RR, et al. Hypersensitivity pneumonitis: evaluation with CT. *Radiology*. 1989;173: 441–445.
39. Silva CI, Muller NL, Lynch DA, et al. Chronic hypersensitivity pneumonitis: differentiation from idiopathic pulmonary fibrosis and nonspecific interstitial pneumonia by using thin-section CT. *Radiology*. 2008;246:288–297.
40. Maier LA, Martyny JW, Liang J, et al. Recent chronic beryllium disease in residents surrounding a beryllium facility. *Am J Respir Crit Care Med*. 2008;177:1012–1017.
41. Muller-Quernheim J, Gaede KI, Fireman E, et al. Diagnoses of chronic beryllium disease within cohorts of sarcoidosis patients. *Eur Respir J*. 2006;27:1190–1195.
42. Kreiss K, Mroz MM, Zhen B, et al. Epidemiology of beryllium sensitization and disease in nuclear workers. *Am Rev Respir Dis*. 1993;148:985–991.
43. Kreiss K, Wasserman S, Mroz MM, et al. Beryllium disease screening in the ceramics industry. Blood lymphocyte test performance and exposure-disease relations. *J Occup Med*. 1993;35:267–274.
44. Newman LS, Buschman DL, Newell JD Jr, et al. Beryllium disease: assessment with CT. *Radiology*. 1994;190:835–840.
45. Kelleher P, Pacheco K, Newman LS. Inorganic dust pneumonias: the metal-related parenchymal disorders. *Environ Health Perspect*. 2000;108(Suppl 4):685–696.
46. Dunlop P, Muller NL, Wilson J, et al. Hard metal lung disease: high resolution CT and histologic correlation of the initial findings and demonstration of interval improvement. *J Thorac Imaging*. 2005;20:301–304.
47. Enriquez LS, Mohammed TL, Johnson GL, et al. Hard metal pneumoconiosis: a case of giant-cell interstitial pneumonitis in a machinist. *Respir Care*. 2007;52:196–199.
48. Kreiss K, Gomaa A, Kullman G, et al. Clinical bronchiolitis obliterans in workers at a microwave-popcorn plant. *N Engl J Med*. 2002;347:330–338.
49. Akpinar-Elci M, Travis WD, Lynch DA, et al. Bronchiolitis obliterans syndrome in popcorn production plant workers. *Eur Respir J*. 2004;24:298–302.

 © 2009 Lippincott Williams & Wilkins